

## **Albinism in US Charolais cattle**

U. JAYASEKERA and H.W. LEIPOLD

*Department of Pathology, College of Veterinary Medicine,  
Kansas State University, Manhattan, Kansas 66506, U.S.A.*

### **Summary**

Complete albinism occurred in 7 calves in two purebred Charolais herds. One calf exhibited nystagmus, opisthotonus and solar dermatitis. All calves had photophobia, acting blind in bright daylight. Two calves were necropsied. Irides, retina, skin and hooves contained scanty amounts or no pigment. Ganglionic layer of retina had a paucity of neurons. Inheritance of this defect is likely to be recessive.

### **1. - Introduction**

Various types of partial or incomplete albinism have been reported in many breeds of cattle such as *Holsteins*, *Guernseys* and *Aryshires* (PETERSON *et al.*, 1944), *Herefords* (LEIPOLD & HUSTON, 1966), a *Zebu* breed (ROY, 1974), *Swiss Simmentals* (WEBER *et al.*, 1973) and others as reviewed by LAUVERGNE (1968). Complete albinism has been documented only in one *Guernsey* male calf (LEIPOLD *et al.*, 1968), one Austrian *Murboden* female (SCHLEGLER, 1959), 4 Beef *Shorthorns* (GREENE *et al.*, 1973) and *Brown Swiss* calves (WINZENRIED & LAUVERGNE, 1970).

Reported here is complete albinism in purebred *Charolais* calves.

### **2. - Material and methods**

Defective calves for this investigation were part of a long-term study of congenital defects in cattle (LEIPOLD *et al.*, 1972, LEIPOLD, 1978). Calves were observed clinically, were humanely euthanitized and necropsied immediately. Tissues were taken from brain, spinal cord, eyes, endocrine glands, internal organs and skin. Tissues were fixed in 10 p. cent buffered, neutral formalin, processed routinely, sectioned at 6 microns and stained with hematoxylin and eosin (H & E).

### 3. - Clinical history

Complete albinism was reported from two purebred *Charolais* herds. The first calf brought to us was a 2-week-old purebred bull *Charolais* calf, and it was presented to us because of blindness. Six such blind calves were seen over a 5 year period in this purebred Kansas *Charolais* herd. They were sired by the same bull and all 5 dams were half sisters. One dam had an albino calf in successive years. After removal of the bull no more cases of albinism were observed. Bull and all dams involved had normal eye color.

A 5-week-old male purebred *Charolais* calf from a 50 head purebred cow *Charolais* herd in Missouri was presented to us in lateral recumbency. It had opisthotonus, nystagmus, and appeared to be blind. The owner had not encountered any other animal with pigmentary anomalies previously. The animal was euthanatized and necropsied.

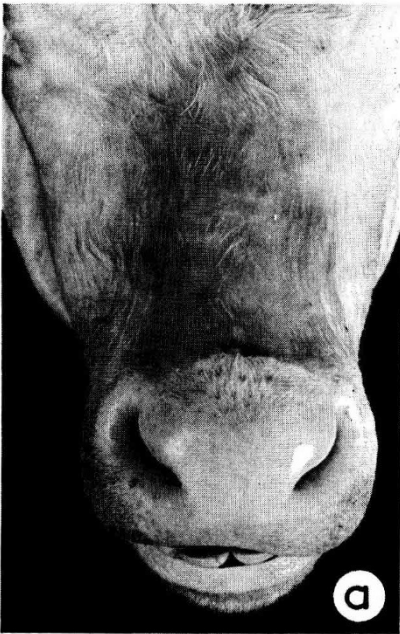


FIG. 1 a

*Facial skin of a purebred Charolais calf affected with complete albinism*  
*Peau de la face d'un veau Charolais de race pure affecté d'albinisme complet*

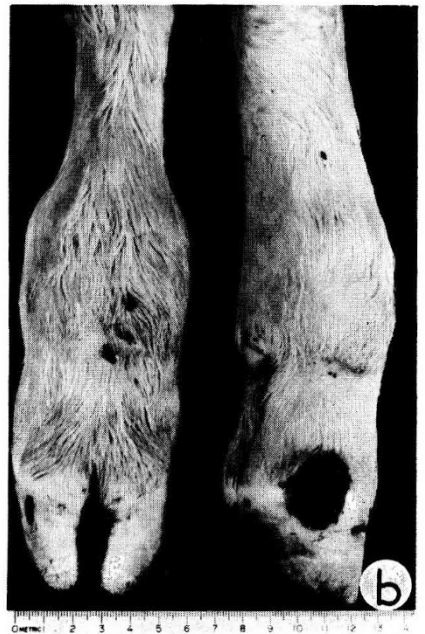

FIG. 1 b

*Legs of a purebred Charolais calf affected with complete albinism*  
*Pattes d'un veau Charolais de race pure affecté d'albinisme complet*

#### 4. - Gross pathologic changes

Both calves necropsied had skin which was whitish to pink and the hair was white and silky (fig. 1a and 1b). Areas around eyelids lacked pigment. The tongue was whitish-pink and hooves were yellowish-white. Skin over face, head and distal limbs revealed lesions of solar dermatitis and had a tendency to peel off (fig. 1a and 1b).

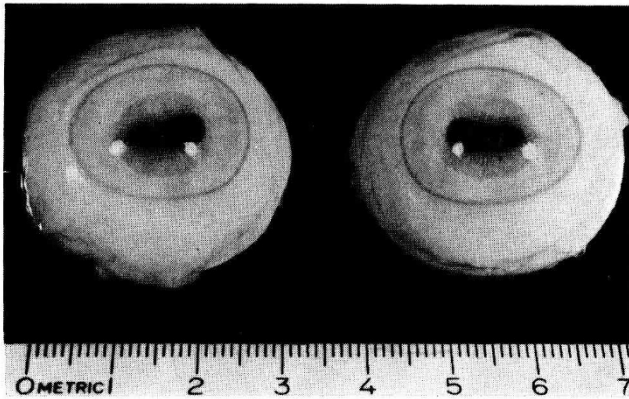


FIG. 2

*Enucleated eyes of a purebred Charolais calf affected with complete albinism.  
Notice white iris color with a fainter center*

*Œil énucléé d'un veau Charolais de race pure affecté d'albinisme complet.  
Noter l'iris blanc, délavé au centre*

The irides were faintly pink (fig. 2). Whitish conjunctiva were densely injected with blood. Ocular fundi were pink and vessels of the retina were prominent. In transverse sections, the tapetum nigrum and tapetum lucidum were indistinguishable and were pigmentless.

#### 5. - Histopathologic changes

None of the layers of epidermis had melanin. Hairs were devoid of pigment. Epidermis was thin. Some sections of skin had mild infiltration of polymorphonuclear leukocytes in the dermis.

Retinal pigment layers did not contain pigment and scanty amounts were present in the ciliary body and limbus (fig. 3). Irides were completely free of pigment. A paucity of neurons was observed in the ganglionic layer of the retina.

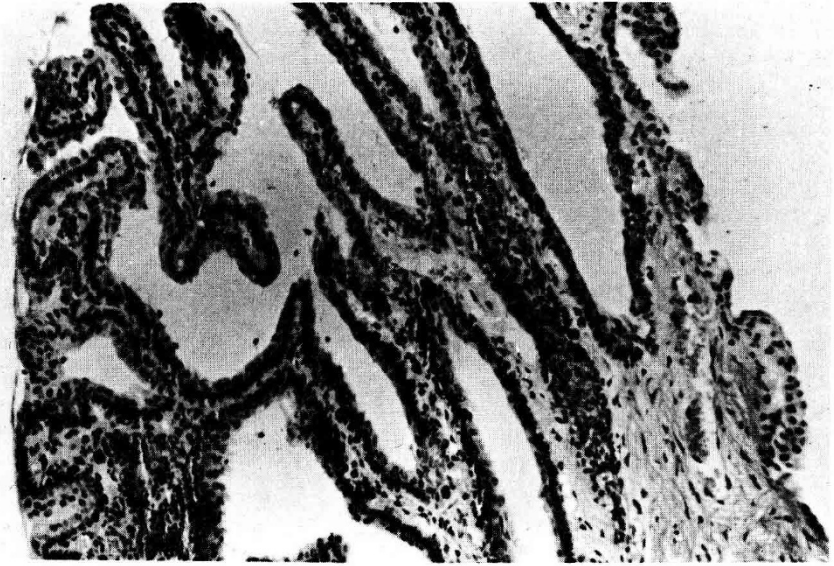


FIG. 3

*Photomicrograph of ciliary body of a purebred Charolais calf affected with complete albinism. Notice complete lack of melanin granules. H & E, 120X*

*Microphoto des corps ciliaires d'un veau Charolais de race pure affecté d'albinisme complet. Noter l'absence totale de granules mélaniques. H et E, 120X*

## 6. - Discussion

Coat color in animals is dependent on the amount of pigment in epidermis, depth at which it is located, and density of the medium between pigment and light scattering surface (FOX, 1953). Mammalian coat color is almost entirely dependent on presence or absence of melanin in the skin and hair, while eye color is determined by intraocular melanin and hemoglobin (SEARLE, 1968). In mammals, melanins exist in distinct forms as eumelanin (brown or black) and pheomelanin (yellow or reddish). Thus, the genetics of coat color in mammals is largely concerned with hereditary factors affecting these pigment granules by altering their number, shape, arrangement and position or by substituting one type of melanin to another (FOX & VEVEERS, 1960). Eumelanin is derived from tyrosine and converted to dopa (3,4-dihydroxyphenylalanine) by catalytic action of the enzyme tyrosinase. DOPA is then oxidized to dopa quinone, undergoes further oxidation and polymerization to become melanin (HARRIS, 1959). Genes may act on any of the biochemical steps in the synthesis of melanin within the cell, and thus result in abnormal coat color (FITZPATRICK *et al.*, 1958).

Clinical, ophthalmologic and microscopic findings in the present case are consistent with complete albinism as elaborated by LAUVERGNE (1968), LEIPOLD *et al.*

(1968), & GREENE *et al.* (1973). Tapetal hypoplasia and optic disc colobomas as described by GELATT *et al.* (1969) were not observed in these albinotic *Charolais* calves.

Albinism appears to be a rare defect. In *Swiss Brown* cattle in Switzerland, the recessive gene was estimated to house a frequency of 0.002 (WINZENRIED & LAUVERGNE, 1970). In a US survey of bovine birth defects involving over 70,000 births, no albinos were encountered, making the frequency of the albino gene, if recessive, to be less than 0.004 (LEIPOLD *et al.*, 1972). GREENE *et al.* (1973) concluded that the type of inheritance of albinism in *Beef Shorthorns* appeared to be recessive. The pattern of occurrence of albinism in these two purebred *Charolais* herds is suggestive of a recessive mode of inheritance. However, further investigations are warranted to elucidate the exact nature of inheritance of complete albinism among *Charolais* cattle.

### Résumé

#### *Albinisme de bovins Charolais aux Etats-Unis*

Sept veaux complètement albinos sont apparus dans deux élevages de bovins *Charolais* en race pure aux États-Unis. Un des veaux présentait du nystagmus, de l'opisthotonus et une dermatite solaire. Deux veaux ont été disséqués. L'iris, la rétine, la peau et les sabots contenaient très peu, ou pas du tout, de pigment. La couche ganglionnaire de la rétine était pauvre en neurones. Le déterminisme héréditaire de cette anomalie est probablement récessif et la fréquence du gène dans la race assez basse.

### References

- FITZPATRICK T.B., BRUNET P. and KUKITA A., 1958. The nature of hair pigment, *In : The Biology of Hair Growth*. Edited by Montagna W. and Ellis R.A., Academic Press, New York.
- FOX D.L., 1953. *Animal biochromes and structural colours*. Cambridge University Press, Cambridge.
- FOX H.M. and VEVERS H.G., 1960. *The nature of Animal Colours* Sidgwick and Jackson, London.
- GELATT K.N., HUSTON K. and LEIPOLD H.W., 1969. Ocular anomalies of incomplete albino cattle : ophthalmic examination. *Am. J. vet. Res.*, **30**, 1313-1316.
- GREENE H.J., LEIPOLD H.W., GELATT K.M. and HUSTON K., 1973. Complete albinism in *Beef Shorthorn* calves. *J. Hered.*, **64**, 189-192.
- HARRIS H., 1959. *Human biochemical genetics*. Cambridge University Press, Cambridge.
- LAUVERGNE J.J., 1968. Catalogue des Anomalies héréditaires des Bovins (*Bos taurus* L.). *Bull. tech. Dép. Génét. anim.*, **1** (I.N.R.A.).
- LEIPOLD H.W., DENNIS S.M. and HUSTON K., 1972. Congenital defects in cattle : Nature, cause and effect. *Adv. Vet. Sci. Comp. Med.*, **16**, 103-150.
- LEIPOLD H.W., HUSTON K., 1966. A herd of glass-eyed albino Hereford cattle. *J. Hered.*, **57**, 179-182.

- LEIPOLD H.W., HUSTON K., GELATT K.N., 1968. Complete albinism in a Guernsey calf. *J. Hered.*, **59**, 218-220.
- LEIPOLD H.W., 1978. Genetics and Disease. 11th Proc. American Assoc. *Bovine Practitioner*, 18-31.
- PETERSON W.E., GILMORE L.O. and FITCH J.B., 1944. Albinism in cattle. *J. Hered.*, **35**, 135-144.
- ROY J.S., 1974. Observation on the albinism in a breeding bull in Uttarpradesch. *Indian Vet. J.*, **51**, 654-655.
- SCHLEGLER W., 1959. Auftreten eines Albinokalves bei der Murbodnerrasse. *Wien. tierärztl. Mschr.*, **46**, 196-199.
- SEARLE A.G., 1968. *Comparative Genetics of Coat Colours in Mammals*. Academic Press, New York.
- WEBER W., LAUVERGNE J.J., WINZENRIED H.W., 1973. Albinisme héréditaire en race *Tachetée rouge* de Suisse. *Schweiz. Arch. Tierheilkd.*, **115**, 142-144.
- WINZENRIED H.U., LAUVERGNE J.J., 1970. Spontanes Auftreten von Albinos in der *Schweizerischer Braunviehrasse*. *Schweiz. Arch. Tierheilkd.*, **12**, 581-587.