

HEREDITARY OSTEOPETROSIS IN *ABERDEEN-ANGUS* CALVES

I. — PATHOLOGICAL CHANGES

H. W. LEIPOLD, K. HUSTON, S. M. DENNIS and M. M. GUFFY (*)

*Kansas Agricultural Experiment Station,
Manhattan, Kansas 66502, USA*

SUMMARY

Twenty-three *Aberdeen Angus* calves with a congenital mandibular defect, brachygnathia inferior with impacted molars and a generalized bone disorder, osteopetrosis, were encountered in 3 *Aberdeen Angus* herds in the United States. Two calves were necropsied and the heads of 4 others were examined. Facial and cranial bones were dense and thickened and all foramina were hypoplastic or aplastic. The cranial base, vertebrae, and long bones were solid and lacked marrow cavities. Microscopically, the cranial base, vertebrae, long and phalangeal bones had fewer blood vessels and a disturbed relationship between bone formation and bone resorption. Gross and microscopic finding in bovine osteopetrosis were similar to those in human congenital osteopetrosis.

Congenitally anomalous calves may be brought to the attention of the veterinarian for several reasons: his obstetrical or remedial surgical skills, or his opinion as to the cause. If it is environmental, the owner may be able to alter herd management to prevent reoccurrence; if it is hereditary, he may alter the herd breeding program. The latter is involved in the recent occurrence of a generalized osteologic defect in 3 *Aberdeen Angus* herds. Gross and microscopic changes of the defect are reported here.

(*) From the Department of Pathology, (Contribution No. 144, Leipold and Dennis) and the Departments of Dairy and Poultry Science (Contribution No. 767, Huston); and Surgery and Medicine (Contribution No. 93, Guffy), Kansas Agricultural Experiment Station, Manhattan, Kansas 66502, U.S.A. This research was part of the North Central Regional Dairy Cattle Breeding Project NC-2.

I. — MATERIALS AND METHODS

The deformed calves were reported in connection with a previously described long-term study of the nature and cause of congenital defects in domestic animals (Huston and Wearden, 1958; Leipold and Huston, 1968). Herd histories were obtained by personal visits and mail inquiries.

Although 23 calves in 3 herds were reported with the defect, only 7 were received for clinical or pathological examination. Three from Herd 1 were examined on the ranch; 2 and the partially autolyzed head of the third were subsequently transported to Kansas State University for necropsy. Later, frozen heads from 3 other calves also were examined. One calf from Herd 3 was examined on the ranch and transported to the University for clinical but no pathologic examination.

Heads and bones were sawed in half; frozen specimens were thawed in 10 % neutral buffered formalin. One half was examined radiographically and histologically; the other half was macerated except for the autolytic head which was entirely macerated. The following tissues were taken for routine histologic examination: cerebrum, cerebellum, spinal cord, pituitary, thyroid, parathyroids, adrenal glands, liver, kidney, spleen, and lymph nodes. Tissues were fixed in 10 % neutral buffered formalin, embedded in paraffin, and sectioned at 6 micra. In addition to routine staining with hematoxylin and eosin (H et E), special stains, PAS, Alcian blue and Mason's trichrome, were used.

Histologic sections were taken from several long bones, phalangeal and carpal bones, vertebrae, mandibles, base and vault of the cranium. Longitudinal and transverse sections of the bones were made at various levels. For comparison similar sections were taken from 2 Aberdeen Angus stillbirths. Sections were decalcified in 20 % formic, sectioned and stained routinely with H et E, Alcian blue, Mason's trichrome, and van Gieson's stain.

II. — RESULTS

A. — Herd histories

Herd 1 was extremely well-managed and comprised 950 registered and grade breeding *Aberdeen Angus* cows. The cows were inseminated artificially commencing December 15 while on a diet supplying 15 lb. TDN and 1.25 lbs. protein daily. In March, bulls were turned in to breed any nonpregnant cows.

In the early 1960's, an abnormal calf was born that may have been the first with osteopetrosis. Five more were born in 1967 and 5 in 1968. All but 1 were born dead. Fetal age of the first 7 of those 10 were 253, 251, 268, 276, 264, 250, and 272 days, respectively, an average of 262 days or about 3 weeks premature. Seven of the 11 calves were by 1 bull; the remaining 4 by 4 other bulls.

Herd 2 was a well-managed herd of 350 registered and grade *Aberdeen Angus* cows. One abnormal calf was born in 1967 and 3 in 1968. All were by a single bull and all but one were from daughters of another bull.

Herd 3 included 90 grade *Aberdeen Angus* cows, half calving in the fall and half in the spring. In 1968, 7 calves with abnormal jaws were born 3 to 6 weeks premature; all were by a single bull and from daughters of another bull. In 1969 one abnormal was from a sister of the 1968 abnormal, sired by another bull.

B. — *Gross pathological changes*1° *Skeletal system*

The external features of the 4 calves seen in their entirety, 3 from Herd 1 and one from Herd 3, were similar. All calves were small; the two necropsied weighed 14 and 22 kilograms. The mandibles were immobile, up to 4 cm. shorter. The mouth was open and the tongue protruded (fig. 1, *a*). The incisor teeth were not completely erupted, and the molar teeth were irregular and impacted.

The cranial cavity was smaller than normal and each had bony closure defects of 1 to 3 cm. in diameter between frontal and parietal bones (fig. 1, *b*). All facial and cranial bones were thicker (0.6 to 0.8 cm.) and denser than normal. Transversely rising folds occurred on the internal cranial vault and were particularly marked at the frontal bones and orbital wings of the sphenoid: the basi-sphenoid bones either lacked nutritive foramina or were stenotic; one specimen already had an ossified sphenoidal-occipital synchondrosis (fig. 2, *a*). The infra-orbital, supraorbital, major palatinal, and ethmoidal foramina were either poorly indicated, some ended blindly after a short distance, or were absent. None of the mandibles had any indication of mental foramina (fig. 1, *a*). The bony accommodation of the optic chiasms was irregular and smaller than normal, and the optic canals were narrow (fig. 2, *a*).

Mandibles were markedly compressed longitudinally, and medio-laterally resulting in malocclusion. The mandibular rami were incomplete and did not articulate normally with the squamous temporal bone (fig. 1, *b*). The intra-alveolar border was extremely short and the molar teeth were misplaced and impacted. Toothbuds of 2 incisors and 2 molars were horizontal and lateral to the other teeth.

All long bones were tough to cut but broke easily under moderate lateral pressure. Upon longitudinal section, the long bones had a solid "bone within bone" appearance due to lack of marrow cavities. Both the epiphyses and metaphyses contained dense endochondral bone (fig. 2, *b*).

Radiographically all the vertebrae had a sandwich-like, compressed appearance. In longitudinal section, the vertebrae appeared compact, and the wedges of endochondral bone were readily discernible.

2° *Other systems*

The central nervous system accommodated the osteologic defects. The cerebral hemispheres were rectangular and the cerebellum was compressed (fig. 1, *a*). Other internal organs were normal.

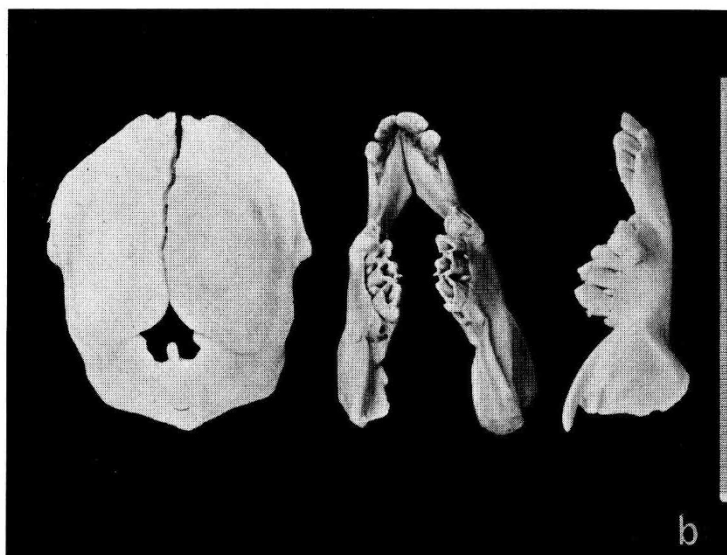
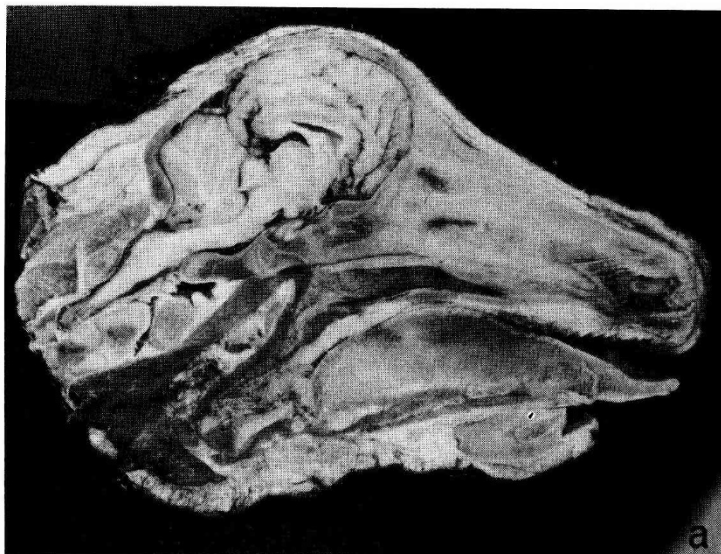


FIG. 1. — a) Longitudinal bisection of head of an Aberdeen Angus calf affected with congenital osteopetrosis. Note short lower jaw, compressed cranial base, abnormal shape of cranium and compressed cerebrum and cerebellum.

b) The cranium has a closure defect between frontal and parietal bones (1). The supraorbital sulcus is poorly indicated and lacks foramina. Dorsal (2) and lateral (3) views of mandibles with impacted molars, abnormal mandibular rami, and lack of mental foramen.

FIG. 1. — a) Coupe longitudinale de la tête d'un veau Aberdeen-Angus atteint d'ostéopétrose congénitale. Noter la brièveté de la mandibule, l'aplatissement de la base du crâne, la forme anormale du crâne, la compression du cerveau et du cervelet.

b) Le crâne offre un défaut de fermeture entre les frontaux et les pariétaux. Le sillon supra-orbitaire est peu marqué et dépourvu d'orifices (1). Vues dorsale (2) et latérale (3) de mandibules avec les molaires télescopées; la branche mandibulaire est anormale et le trou mentonnier fait défaut.

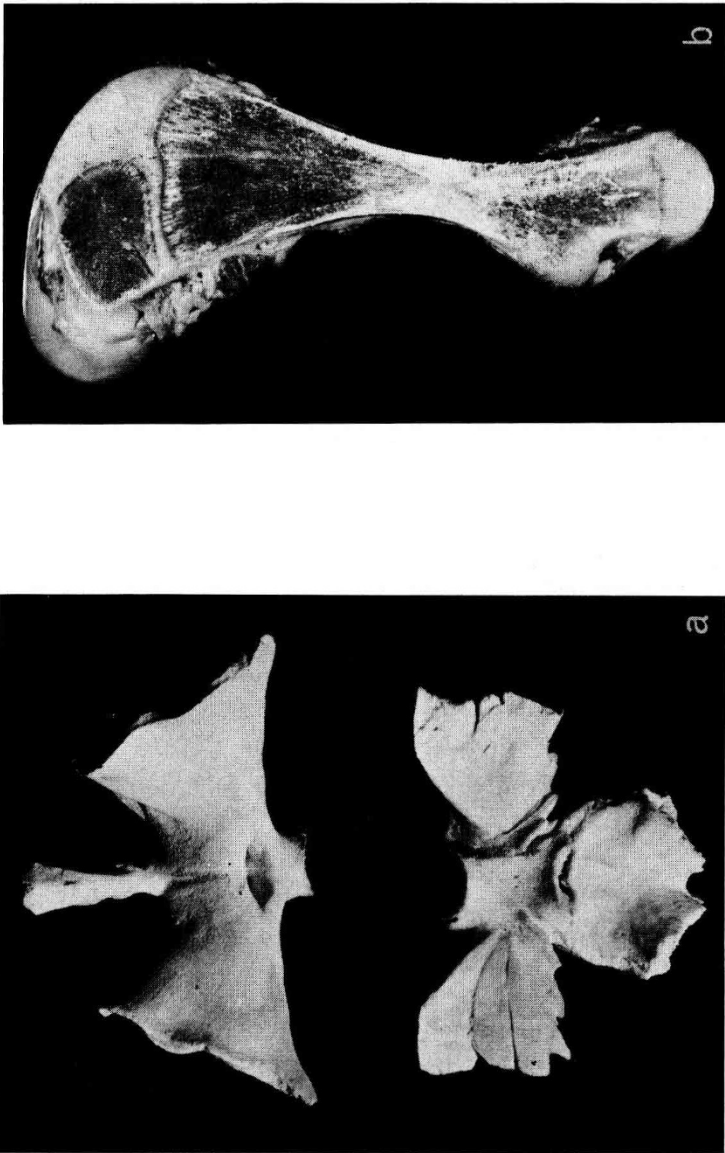


FIG. 2. — a) Presphenoid and basisphenoid bones. Note narrow optic foramina, ridges on wing of sphenoid, and synostosis of basisphenoid-occipital synchondrosis.

b) Longitudinally bisected femur of an osteopetrotic calf. Note wedges of endochondral bone in metaphyses and lack of marrow cavities.

FIG. 2. — a) Os présphénoïde et basisphénoïde. Noter l'étroitesse des trous optiques, l'existence de crêtes sur les ailes du sphénoïde et la synostose de la synchondrose basisphéno-occipitale.

b) Section longitudinale du fémur d'un veau atteint d'ostéopétrose. Noter les poussées d'os endochondral dans les métaphyses et l'absence de cavité médullaire.

C. — *Histopathological changes*1° *Skeletal system*

The nasal, frontal, temporal, parietal and maxilla bones were denser than normal with evidence of deposition of bone on the outer surface but no bone removal from the inner surface. Pockets of marrow and small foci of fine connective tissue were interspersed throughout these bones. Median and paramedian sections of the cranial base had irregular intersphenoidal and speno-occipital synchondroses. From both synchondroses, apices of wedge-shaped endochondral bone extended into solid cortical bone. The endochondral bone wedges consisted of calcified matrix and osteoid, occasional islands of resting chondrocytes and a few small foci of marrow. The sparsity of the vascular supply was striking. The growth plates of the vertebral bodies were irregular due to broad spicules of hypertrophied chondrocytes. Wedges of endochondral bone extended from the growth plates and their apices joined in the approximate center. The sides of the wedges were surrounded by dense cortical bone. Evidence of bone resorption was absent.

The long bones had similar microscopic features. The articular surfaces were normal. The epiphyses consisted of primary spongiosa. The epiphyseal plates were irregular due to spicules of hypertrophied chondrocytes protruding towards the metaphyses (fig. 3, *a*). Islands of the hypertrophied chondrocytes were present in metaphyses. Calcified matrix arising from the epiphyseal plates was dense and persisted throughout the endochondral bone core. Marked osteoid seams were formed around the calcified cartilagenous matrix (fig. 3, *b*). The metaphyses contained calcified cartilagenous matrix, osteoid, and osseous tissue. Some osteoclasts were observed but they appeared inactive. Few penetrating vessels were observed. Marrow spaces were limited, visible blood vessels were few and dilated and the hematopoietic tissue was sparse. Numerous areas of potential pockets of marrow cavities were replaced by a network of fine connective tissue. Cross-sections of bone in the metaphyseal and diaphyseal areas revealed narrowing of marrow spaces by cartilagenous matrix and osteoid, and by surrounding encroaching cortical bone (fig. 3, *b*). Upon transverse and longitudinal sections, the middle of the diaphyses had dense compacted cortical bone which contained a few foci of marrow and loose connective tissue. The center of the diaphyses contained a narrow core of endochondral bone. Signs of bone resorption and remodelling were lacking. Longitudinal sections of phalangeal bones had a wedge of endochondral bone, the apex of which met distally with dense cortical bone in a V-shaped line.

2° *Other systems*

The central nervous system had petechial hemorrhages in the cerebrum and cerebellum. A few smaller blood vessels, specifically dural vessels over the cerebellum, were calcified. The parathyroid glands were small but not

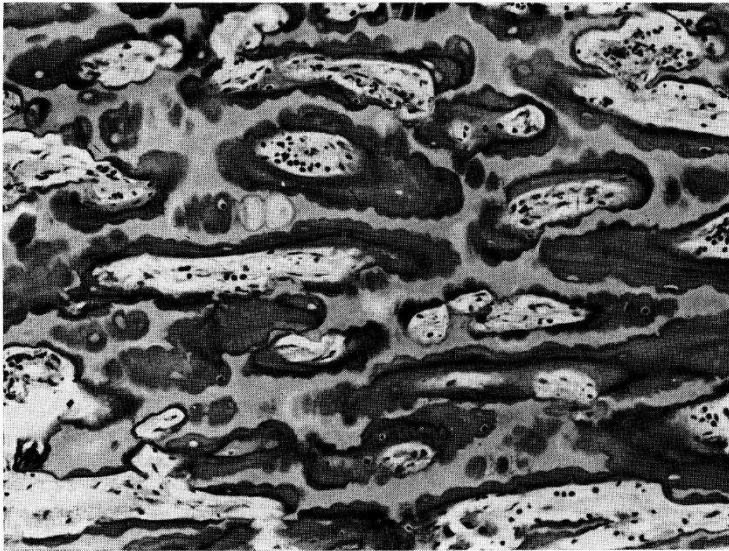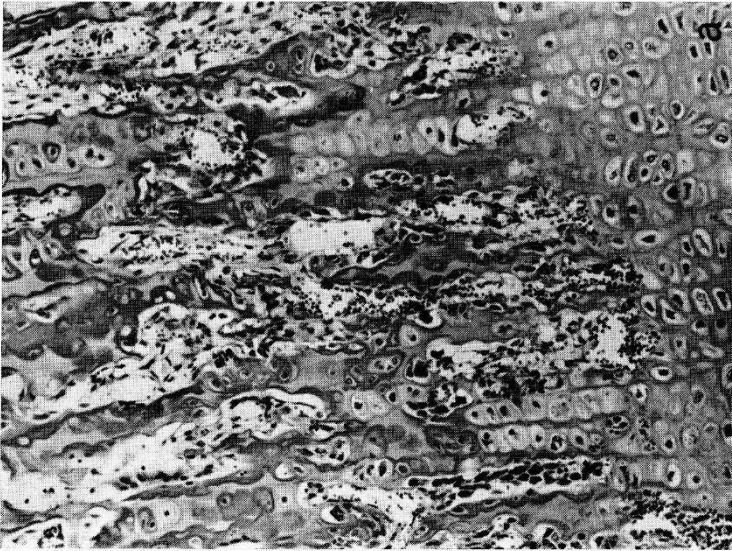


FIG. 3. — a) Photomicrograph of longitudinal section of proximal growth plate of humerus. Note proliferation of hypertrophic chondrocytes into the metaphysis, H et E, 120 X.

b) Photomicrograph of longitudinal section from diaphysis of femur. Note persistence of heavily calcified, cartilaginous matrix and formation of osteoid further narrowing potential medullary lumen. The cortical bone is dense and resorption is lacking. Trichrome stain, 120X.

FIG. 3. — a) Microphotographie d'une section longitudinale du cartilage de conjugaison proximal de l'humerus. Noter la prolifération des chondrocytes hypertrophiques dans la métaphyse. H. et E. 120X.

b) Microphotographie d'une section longitudinale de la diaphyse du fémur. Noter la persistance d'une matrice cartilagineuse très ossifiée, la formation d'ostéoides qui rétrécissent la lumière médullaire. L'os cortical est dense et la résorption osseuse fait défaut. Coloration au trichrome, 120X.

histologically different from parathyroids of normal neonatal calves. The liver, spleen, and lymph nodes contained numerous foci of extramedullary hematopoiesis. Other tissues were normal.

III. — DISCUSSION

This defect has recently been diagnosed twice in the *Aberdeen-Angus* breed: once in the United States (THOMPSON, 1966) and once in Canada (LEIPOLD *et al.*, 1970). Because there are some common ancestors in the Saskatchewan (Canada) cases and the present ones, the title "hereditary osteopetrosis" is appropriate. The genetic study will be presented in a following paper.

Osseous anomalies comprise a considerable part of the whole spectrum of congenital defects in cattle. They may be restricted to certain regions of the body or may be generalized. The defect described here is generalized and is readily recognizable by such gross features as brachygnathia inferior and impacted molars, and lack of bone marrow cavities.

Some congenital osteologic defects affecting bovine jaws are restricted to the jaws; others are generalized. Hereditary brachygnathia inferior resulting from a disparity in length of the jaws has been described in several breeds; agnathia, a hereditary lethal, also has been noted (LAUVERGNE, 1968). However, no similar case in *Aberdeen-Angus* has been reviewed by LAUVERGNE (1968). The nearest condition (No. 58 of the catalogue) has appeared in *Milking Shorthorns* in the United States, New Zealand and Great Britain under the name of "impacted molars". The bones of those cattle were neither radiographed nor examined grossly. Whether the two congenital diseases (brachygnathia inferior with malformed, impacted molars) and that described here are the same remains to be clarified.

Gross and microscopic lesions described in the present paper correspond to those encountered in human congenital osteopetrosis. Although, the condition appears to be an imbalance between bone formation and bone resorption, the basic mechanism is obscure. Injecting parathormone and vitamin D failed to improve a child affected with congenital osteopetrosis (FRASER *et al.*, 1968).

Reçu pour publication en mai 1971.

RÉSUMÉ

OSTÉOPÉTROSE HÉRÉDITAIRE EN RACE *Aberdeen-Angus*

I. — MODIFICATIONS PATHOLOGIQUES

Au sein de trois troupeaux *Aberdeen-Angus* aux Etats-Unis, on a relevé, dès la naissance, chez vingt-trois veaux, une anomalie congénitale de la mandibule sous forme de brachygnathie inférieure avec déformation de l'arcade molaire, accompagnée d'altérations osseuses généralisées (ostéopétrose). Deux veaux furent autopsiés, la tête de quatre autres fut examinée. Les os de

la face et du crâne apparaissent épaissis et tous les orifices crâniens sont hypoplastiques ou aplastiques. La base du crâne, les vertèbres et les os longs sont de consistance ferme et n'ont pas d'espaces ou de cavités médullaires. Au microscope, la base du crâne, les vertèbres, les os longs, les phalanges accusent une raréfaction des vaisseaux sanguins ainsi qu'un déséquilibre entre la formation et la résorption osseuse. Les os crâniens sont denses et épaissis. Sur le plan macroscopique comme sur le plan microscopique, l'ostéopétrose bovine rappelle l'ostéopétrose congénitale de l'Homme.

REFERENCES

- FRASER, D., S. W. KOOB, A. M. CHAN, A. G. CHERIAN, 1968. Congenital osteopetrosis on a failure of normal resorptive mechanisms of bone. *Calc. Tiss. Res.*, **2**, 52.
- HUSTON, K., WEARDEN, S., 1958. Congenital taillessness in cattle. *J. Dairy Sci.*, **41**, 1359-1370.
- LAUVERGNE, J. J., 1968. Catalogue des anomalies héréditaires des bovins (*Bos taurus* L.). *Bull. tech. Dep. Genet. anim.* (Inst. nation. Rech. agron., Fr.), n° 1, 91 p.
- LEIPOLD, H. W., DOIGE, C. E., KAYE, M. M., CRIBB, P. H., 1970. Congenital osteopetrosis in *Aberdeen-Angus* Calves. *Can. Vet. J.*, **11**, 181-185.
- LEIPOLD, H. W., DOIGE, C. E., KAYE, M. M., CRIBB, P. H., 1970. Congenital osteopetrosis in *Aberdeen-Angus* Calves. *Can. Vet. J.*, **11**, 181-185.
- THOMSON, R. H., 1966. Failure of bone resorption in a calf. *Path. Vet.*, **3**, 234-246.
-